

The Eyelid Crease Height, Depth, and Shape: A Scoring System for Revisional Asian Blepharoplasty

William Pai-Dei Chen, MD

Background: This study reports on a series of challenging revisional Asian blepharoplasty cases with various suboptimal factors, including high or low crease height, shallow or deep crease indentation (depth), and suboptimal crease shape. The study also presents a simple scoring scale that combines these challenges into a composite score, which has helped in the management of these cases.

Methods: Data on 64 revisional cases were collected between January 1, 2006, and June 30, 2019, with 126 upper eyelids. These were cases with little skin remaining after previous surgeries, and each eyelid was scored based on a *height, depth, shape scoring method*. A composite score (H + D + S) is then summed up, which ranged from 1 to 10, with the higher number being the most challenging. The logic and rules behind this scoring scale are explained.

Results: Data regarding age, gender, and eyelid crease characteristics of the cases were collected; photographs, notes, and diagrams in the medical records were used to complete each eyelid's scoring. The age of the patients (57 women and 7 men) ranged from 21 to 74 years. The revision score distribution, age distribution, and averaged scores within each age group were investigated for those starting at 24 years or younger, and for each added decade until over 65 years. Patients with revisional effort scores of 5–8 were found in all age groups surveyed.

Conclusions: In this study, the author presents a practical scoring scale that recognizes the factors responsible for the suboptimal results in double eyelid plasty and helps clinicians in management, patient-counseling, and planning of surgical solutions. (Chinese abstract available here: 請從此看論文摘要: <http://links.lww.com/PRSGO/B425>.) (*Plast Reconstr Surg Glob Open* 2020;8:e2802; doi: 10.1097/GOX.0000000000002802; Published online 29 May 2020.)

INTRODUCTION

There has been great progress in the field of double eyelid surgery since Mikamo reported on his suture method¹ to create a lid crease in 1896. The field has since then expanded from the buried sutures method to incisional approaches.^{2–29} Steady progress in reported research findings through the 1980s and 1990s allowed a better understanding of the structures of the upper lids in Caucasians as well as Asians^{4–11}; of these findings, those by Collin et al⁵ and Morikawa et al¹¹ are worth a special mention. There were fewer papers published on Asian eyelid

complications and their corrections. It is this author's experience that easier revisions for post-blepharoplasty lid crease complications are possible in those presenting with at least a few millimeters of residual eyelid skin left, while more difficult revisions involve those with little skin remaining. For those with scarce skin, the author had presented an analysis^{30,31} of a super-beveled revision technique involving 48 eyelids,^{30–33} with an average improvement in lowering (by 2.75 mm) of abnormally high crease height. Additional overviews on Asian blepharoplasty and general crease design are referenced.^{34–37}

Among papers on *revisional corrections*, in 2000, Kim et al³⁸ reported on grafting of preaponeurotic fat and use of septal tissues in unsatisfactory blepharoplasty. In 2004, S. Chen et al³⁹ described their findings on 168 patients seen for corrective Asian lid surgery, and their report focused on patient satisfaction. Kim et al⁴⁰ in 2006 described the

From the Jules Stein Eye Institute, Department of Ophthalmology, UCLA School of Medicine, Harbor-UCLA Medical Center, Torrance, Calif.

Received for publication February 3, 2020; accepted March 6, 2020.

Copyright © 2020 The Author. Published by Wolters Kluwer Health, Inc. on behalf of The American Society of Plastic Surgeons. This is an open-access article distributed under the terms of the *Creative Commons Attribution-Non Commercial-No Derivatives License 4.0 (CCBY-NC-ND)*, where it is permissible to download and share the work provided it is properly cited. The work cannot be changed in any way or used commercially without permission from the journal.

DOI: 10.1097/GOX.0000000000002802

Disclosure: The author has no financial interest to declare in relation to the content of this article.

Related Digital Media are available in the full-text version of the article on www.PRSGlobalOpen.com.

use of fibromuscular tissue graft in secondary blepharoplasty. In 2010, Zhang et al⁴¹ reported on repair of unsatisfactory double eyelid. In 2015, Cho⁴² discussed revision of upper blepharoplasty. Young et al⁴³ in 2018 described crease lowering in revision for Asians; their operative photographs showed a significant excision of skin tissues, with about one-third of patients undergoing ptosis repair.

Suboptimal results obtained after double eyelid procedures may involve *height* or *shape* of the crease, regardless of whether the crease formed is natural (dynamic) or static, continuous or broken, and *deep-set* or rudimentary. Some creases may disappear with time, while others may be only partially formed across the palpebral fissure. Success depends on the clinician's skill in selecting the correct crease *height* (H), constructing it to the optimal *depth* (D) for a dynamic crease, and being able to develop it to the proper desired *shape* (S). The 4 factors to strive for in this regard are height, shape, continuity, and permanence. Clinically significant asymmetry can arise from a deviation from proper height and shape of the eyelid crease, a lack of continuity of crease (partial, segmentation, bifurcation, undesirable widening or narrowing of crease in sections along the palpebral length) on one or both sides, and a lack of permanence (poor crease formation from mid-lamellar scarring or disappearance) (Fig. 1).

Besides the factors mentioned, it is important to understand the concept of the apparent crease height versus the anatomic crease height,⁴⁴ as well as the vulnerability of the levator palpebrae superioris to inexact placement of crease-forming sutures. Chen⁴⁵ discussed the precise placement of crease-forming points and avoidance of locking sutures that may amplify Faden-like (restrictive) effect on the posterior lamella (levator muscle, Mueller's muscle) (see the links to outside Videos 2-4, located in **Supplemental Digital Content 1**, <http://links.lww.com/PRSGO/B372>). Deviation and suboptimal results are magnified among Asian anatomy due to smaller anatomic dimensions.⁴⁶

In revisional cases, besides height and shape, one is often faced with a third factor of suboptimal depth (D) of the crease (being too deep or too shallow) or the dermis of the wound showing wound spreading.

This article presents a series of cases that illustrates how a crease height, crease depth, and shape scoring system can be used to quantitate these findings and helps in management of these revisions.

PATIENTS AND METHODS

Each revisional patient underwent a comprehensive ophthalmic examination, including checking for lid lag, a poor closure of the lid margins, any evidence of extraocular muscles or levator muscle weakness, double elevators' palsy, neuromuscular disorders, Parkinsonism, and myasthenia gravis. Also recorded are the absence or presence of Bell's eye reflex (oculocephalic reflex), any history of dry eyes, or prior corneal refractive procedures that may have induced a degree of dry eye syndrome. The crease height of each upper eyelid was measured with the eyes on downgaze such that the lid and levator were resting passively, using a millimeter scale or a caliper spanning the distance from the crease to the central lid margin. The depth of the scar and the shape of the crease were examined visually. Patients included were those with barely any skin remaining (Fig. 2, yellow box), and who presented with any abnormality in crease height, depth, or shape. The *exclusion criteria* included anyone with strabismus, eyelid malposition of ptosis or upper lid retraction, and systemic or ocular neuromuscular disorders; also excluded were those with some excess skin remaining, who could therefore undergo a standard repeated blepharoplasty. The 64 cases in this series all required the super-beveled revisional Asian blepharoplasty.^{30,31}

Assignment of Revisional Effort Score (RES)

1. Height

- (a) Among revisional patients *with little skin remaining*, correction of the high crease height had been the most challenging task; such patients were assigned a maximum H score of 5 (red down arrow, in crease height column) (Fig. 3).

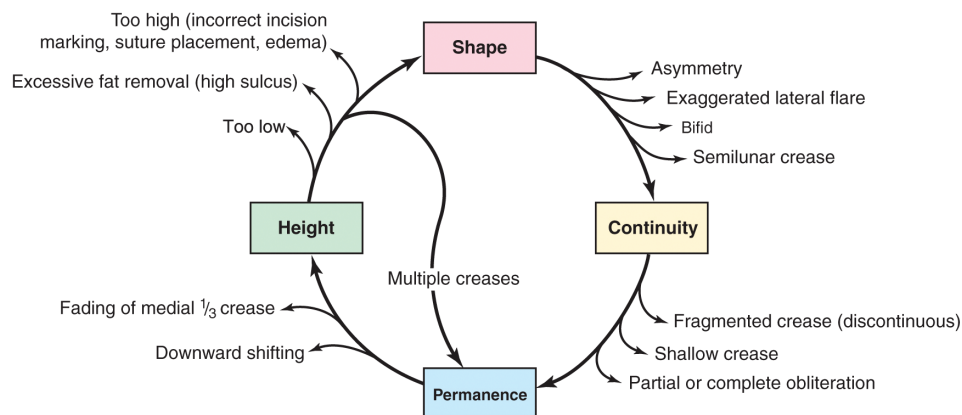


Fig. 1. Circle of parameters and of complications in Asian blepharoplasty—height, shape, continuity, and permanence. Reprinted with permission Chen WPD. *Asian Blepharoplasty and the Eyelid Crease*. 3rd ed. Edinburgh/New York: Elsevier; 2016.

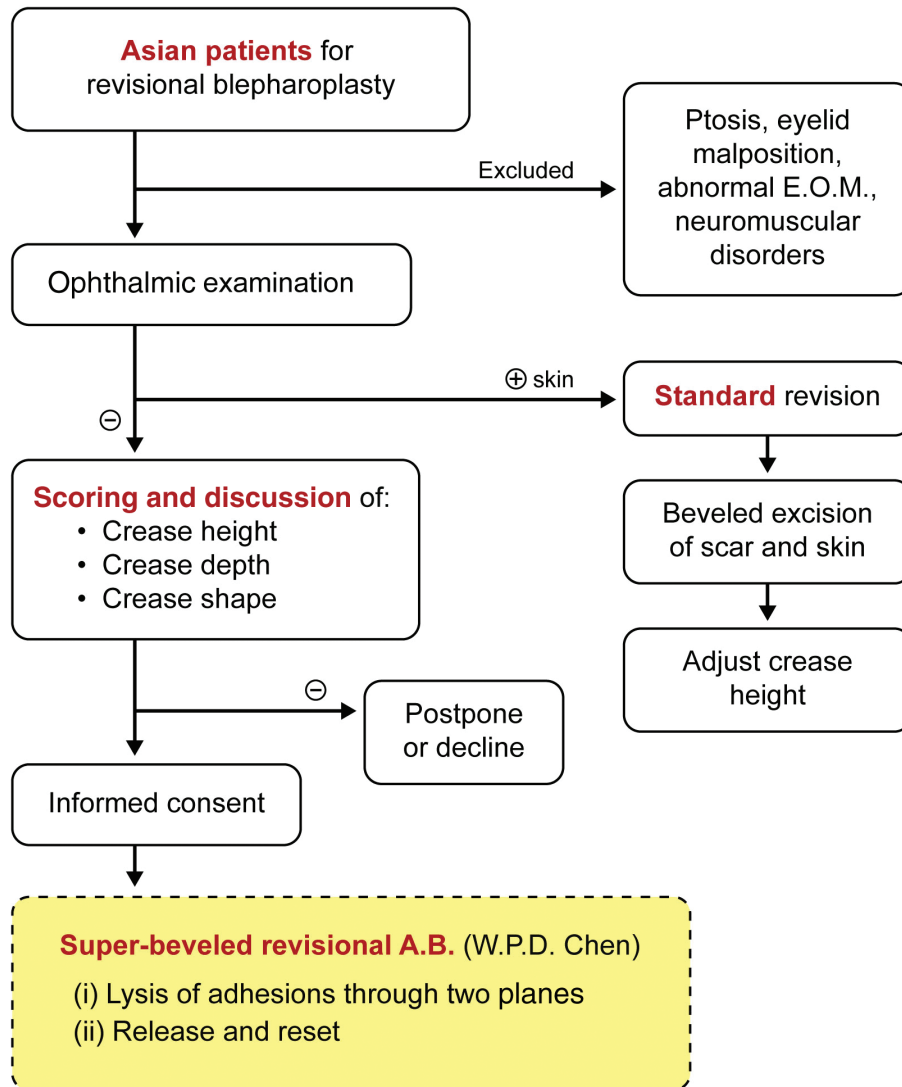


Fig. 2. Clinical pathway: selection criteria in this scoring study of revisional Asian blepharoplasty. Patients included are indicated in the yellow box; all had crease height, depth of scar, and/or crease shape issues and exhibited scarcity of skin. (The patients who had residual skin needed only standard revisional upper blepharoplasty with a proper design of crease height, proper technique to ensure ideal depth, and proper shape design; these are not included in this article.)

- (b) Those needing a raise in low-set crease were assigned a revisional effort H score of 3 (orange up arrow, in height column).

2. Depth

- (a) A crease may be deep set, which correlates with the severity of mid-lamellar tissue scarring; the revision effort needed to correct to a less deep and more dynamic-appearing crease is scored a D value of 3 (orange up arrow in crease depth column).
- (b) A *shallow* or rudimentary crease with insufficient invagination on straight-ahead opened-eye gaze will need enhancement of crease—it is equally scored a D value of 3 (orange down arrow in depth column).

3. Shape

- (a) An upper lid may not have a well-formed crease in its medial segment; in this situation, we assign an S score of 1 to create either a parallel crease shape or a nasally joining crease (NJC) there.
- (b) If a parallel crease shape or NJC exists, and the patient chooses to stay with existing shape, there is no added effort and the S score is zero.

For change of crease SHAPE:

- (c) from NJC to parallel shape is assigned an effort score S of 1 (thin green up arrow, in shape column);
- (d) from parallel shape to NJC is difficult; revisional effort S assigned is 2; the danger here is that the

medial crease may develop into a bifid ending (yellow, down arrow).

Data were collected with regard to age, gender, preoperative findings and discussions in a spreadsheet; scoring was performed by the author for each upper eyelid that underwent revision. Each eyelid was scored in these 3 attributes (H, D, and S scores), and the 3 values are summed up to yield a combined score for each eyelid—ranging from a possible value of 1 to a maximum of 10. A patient may yield different scores for their 2 eyelids.

RESULTS

The age of the patients (total: 64; 57 women and 7 men) ranged from 21 to 74 years. There were 126 eyelids; 2 patients had unilateral revision.

The revisional effort score (RES) (H + D + S) distribution of the 126 eyelids studied is shown in Figure 4. Height, depth, and shape (HDS) score columns are as follows: from 1 to 4 is arbitrarily colored green, signifying a lower level of difficulty in revision; 5, 6, 7, colored yellow, signifying mild difficulty; 8, 9, colored orange, signifying moderate difficulty; and 10, colored red, signifying most challenging.

Of the 126 eyelids, 91 eyelids (72.2%) had scores between 6 and 9, requiring significant revisional efforts. The most frequent score was 8, as shown in 36 eyelids (28.5%). The score bars of 8 and 9 comprised 55 eyelids (43.6%), showing that high crease height (H = 5) was a significant abnormality requiring revision.

Age Distribution

Revision cases were seen in the whole age spectrum (Fig. 5). Those scoring 5–8 (mildly to moderately difficult cases) were seen within *each* age group examined, from the 20s to the 60s. (The 3 cases at 65+ age group had scores of 8, 8, and 9.)

Averaged RESs (H + D + S) per 10 years' age grouping (Fig. 6) are shown as follows: 24 years and below, 6.25; 25–34 years, 7.1; 35–44 years, 7.0; 45–54 years, 6.26; 55–64 years, 6.25; and 65 years and above, 8.3 (with only 3 patients).

Among the 64 patients, the average RES was 6.66. Patients with an RES of 8 or 9 were observed in all age groups. Lower scores of 3, 4, and 5 were also seen among *each* age group; this explains the reason why there were no clearly discernible age patterns among their averaged RES. It meant that these complications (both mild and complex) can be seen among all age groups studied.

The *abnormal crease height (H)* data (Fig. 7) shows that 54% needed revision of abnormally high crease height, scored as H = 5 (68/126; red pie on graph); 31% required correction of an abnormal low crease height, scored as H = 3 (39/126; orange pie); and 15% (19/126; white pie) did not require a change in crease height, scored as H = 0, although most likely revisional effort is still needed within their mid-lamellar plane.

Table 1 outlines the possible findings that contribute to each score value, and the photographs in each figure (Figs. 8–16) and the accompanying legends describe various findings.

DISCUSSION

As mentioned in the Introduction, there have been studies^{38–43} on double eyelid complications and revisions dating back to 2000 to 2018, some of which were where direct excision of the scarred skin, orbicularis and mid-lamellar scarring were possible, and had not mentioned the risk of inducing further lagophthalmos, poor eyelid closure, and dry eyes symptoms. These reports have not described a method either to quantify or to compare the actual findings, and may have consisted of straightforward revisions combined with a lesser number of more difficult cases. In patients without adequate skin, it is not feasible to tackle the problem without risking dry eyes, if one were to directly excise skin scar and adjacent tissues.

Revisional surgeons should possess skills as well as compassion in offering proper counseling to the distressed patients. Patients should have realistic expectations based on their individual findings. It is prudent to wait at least a year for the lid lamellae to soften, before attempting a revision. The use of an RES (HDS score) helps patients understand possible outcomes. It can be useful in managing patient expectations: one may advise that those in the RES range between 5,6,7 (mild difficulty, yellow bars in Fig. 4) may have an average improvement of 50% toward normal parameters—for example, a patient with an abnormal crease height of 10 mm may have it lowered to 8.5 mm (assuming the most common tarsal height for Asians is of 7 mm), thereby reaching 50% of the goal toward a 7-mm crease height; by similar reasoning, a lower RES (green) is more likely to gain a higher percentage correction.

The author encountered an RES that ranged from 1 to 10, with the exception of an RES of 2 in this series. The likely reason is that conversion of a parallel-shaped crease to an NJC will need some residual skin on top of the crease indentation; this is difficult as there is not any spare skin remaining; it runs a high probability of ending up with a scarred bifid crease. The author likely recommended against such an attempt, and therefore none were observed in this series.

Seventy-two percent (91 eyelids) of our cases were of mild-to-moderately difficult RES of 6–9. The average RES overall was 6.66, which is on the higher end of the 1–10 score range.

Often the revisional attempts may come from patients who had undergone *buried sutures methods* (“nonincisional techniques”) and then developed a shallowed crease, or a high crease, or with mild acquired ptosis. Their RES may range from low to high: when the number of buried sutures applied is only 1–3 in total, the crease formed may disappear after a period of time; in these scenarios, the revisions can be fairly uneventful, as one is then performing external incision method for the first time (see the link to outside Video 1, located in **Supplemental Digital Content 1**, <http://links.lww.com/PRSGO/B372>), with a H = 0 and D = 0 due to a relatively little disturbance and S (shape) of 1 as we needed to create a new crease of specific shape (H + D + S = 0 + 0 + 1 = 1). Others may have HDS scores of 3 and 4 as the prior surgery resulted in a low crease height; hence, the H effort value needed to raise the crease to the proper height is 3 (Fig. 14, RES of 4).

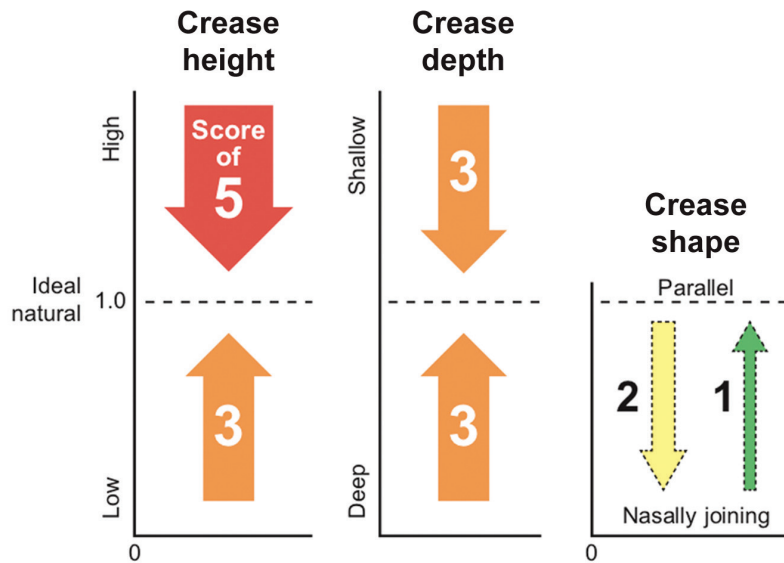


Fig. 3. H (height) correction is based on whether the crease is abnormally high, normal, or abnormally low. Adjusting downward from high crease height toward the direction of normalcy requires an effort score of 5 (red arrow), while to raise an abnormally low crease height to a more ideal position is scored 3 (orange arrow). D (depth) is judged based on whether the existing crease form is abnormally deep (or showed wound spread or skin gapping), whether it is normal depth, or either too shallow or without invagination at all. When showing deep-set crease or a wound spreading, the RES is assigned a value of 3 (up arrow). If the depth is too shallow, with a rudimentary indentation or frank absence of crease, the RES is also assigned 3 (down arrow). S (shape) is judged based on the existing state of the medial portion of the eyelid crease: If absent, and the need is to construct either a parallel shape (“open”) or a nasally joining crease (or “closed”), the RES is 1. Conversion of the shape from NJC to parallel requires an RES of 1; converting parallel to NJC is scored 2. An existing crease shape that is satisfactory and requires no change is scored zero. An existing crease that has an excessive medial upper fold shielding it and therefore requires partial reduction is assigned a score of 1.

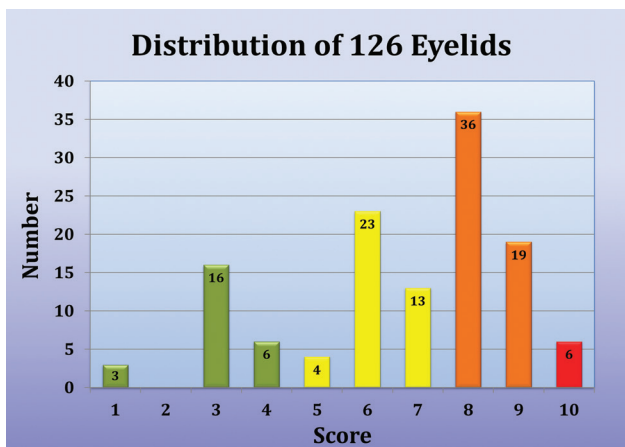


Fig. 4. Distribution of revisional effort scores {composite of H + D + S} for 126 upper eyelids of 64 patients. (Green, yellow, orange, and red are arbitrarily assigned to represent the progression of difficulty level with revisions.)

One variant of the buried sutures method involved placement of a *single continuous suture that ran back and reverse like a hairpin*; here the crease may be seen as high (H = 5), the depth may be either deep or shallow (D = 3), and the S (shape) score may be 0 if no change in shape

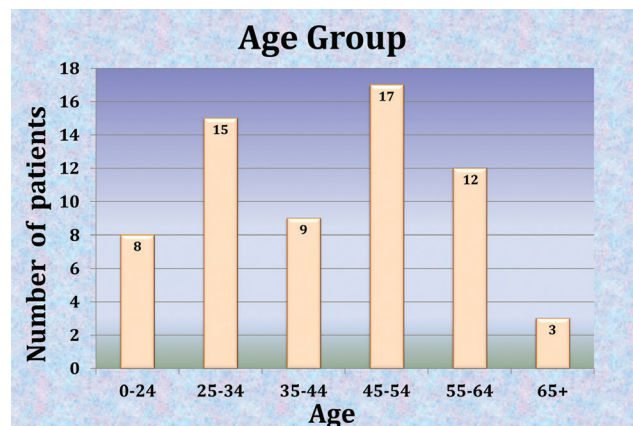


Fig. 5. Age distribution of 64 patients.

is needed, or S = 1 if needed to create the medial end of a crease from absent crease, or other possible S scores of 1 (to change from NJC to parallel), or 2 (to change from parallel to NJC), with the total {H + D + S} being 8, 9, or even 10 (Fig. 10, with RES of 8).

There are *hybrid methods in double eyelid blepharoplasty* that involved a partial external incision (extending from one-third to two-thirds of the palpebral width) plus buried

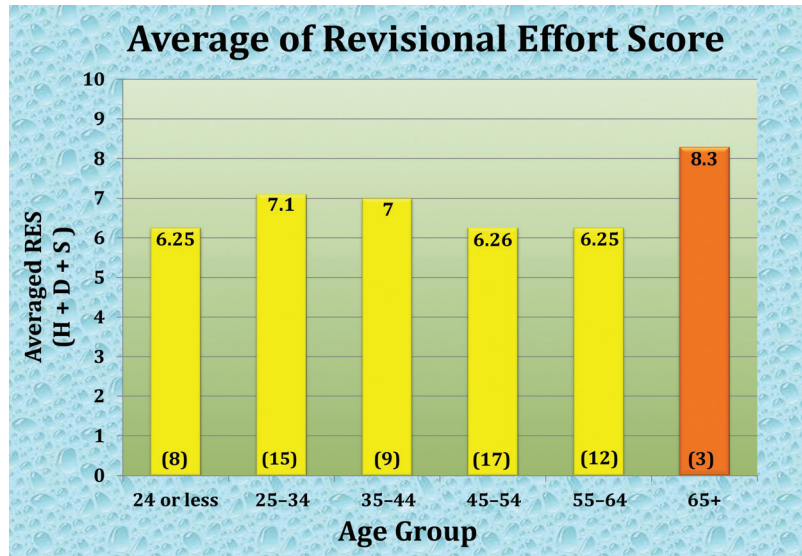


Fig. 6. Averaged HDS scores within each decade of age.

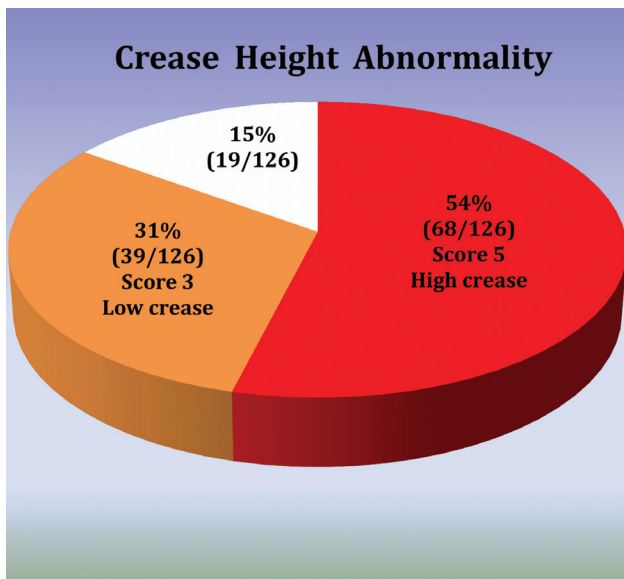


Fig. 7. Incidence of high and low crease height abnormality among scored eyelids.

sutures' placement. The partial incision scar is usually located centrally, with a high crease placement that is either shallow or deep set. It may have an H value of 5, a depth value of 3, and a shape value of either 0 or 1 (0 if no change in shape, and 1 if we needed to enhance a crease that is absent medially); therefore, their HDS score may be 8 or 9. The lesson that the author took away is that suture methods or hybrid methods are not always benign, as they can pose significant revisional challenges.

Preferred Technique

A current literature search of double eyelid complications and revisions showed that the most demanding situation, where there were abnormally high crease height and skin shortage, was published by Chen^{30,31} and mentioned as early as 1995.⁴⁷

A super-beveled approach^{30,31} to traverse through 2 planes to reach remnants of the preaponeurotic space was described (see the link to outside Video 4 in **Supplemental Digital Content 1**, <http://links.lww.com/PRSGO/B372>). Clearance of the preaponeurotic platform, which includes preservation (*reposition*) of fat and *removal* of mid-lamellar scar tissues in the residual preaponeurotic space, as well as *resetting* of anterior and posterior lamellae, was described. With this technique (Fig. 17), the release and corrective off-loading of inhibitive force from high crease placement often resulted in an improvement of levator excursion (travel), as well as reduction or correction of acquired ptosis. This resetting of anterior and posterior lamellae results in *recruitment* of skin from the preseptal (upper) zone and allowed an average lowering of 2.75-mm crease height among the 48 eyelids reported. It had also improved or *restored* the ratio of the {preseptal zone/prearsal segment}.

This study details the challenges in revisional Asian blepharoplasty, and evaluates and assigns a value to each of the 3 main factors (height, depth of scar, and shape). The summed score (RES = H + D + S) indicates the effort required of the surgeon, as well as serves as a common denominator of understanding with our patients. It is used by the author to moderate expectations of outcome in such settings. This can be adjusted based on the clinician. In practice, the author uses this as a *probability estimate* of outcome in advising patients on the 3 factors that may need correction. It helps with "informed consent" and adds an additional screening for individuals who may have abnormal expectations.

Applications of HDS Scoring System

1. Scoring of revisional case series allows a comparison between different series regarding whether it is from the same clinician or from different clinicians.
2. It allows a comparison on the efficacy of *different* corrective techniques, when comparing several series of similar HDS scores.

Table 1. The Combination of Findings That Contribute to Each RES (or HDS Score)

HDS Score	Findings
10 [5, 3, 2]	High crease height; either deep/shallow scar; shape change to NJC (Fig. 8)
9 [5, 3, 1]	High crease; deep or fading of crease; shape change to parallel (or create a crease medially) (Fig. 9)
8 [5, 3, 0]	High crease; deep/shallow scar; crease shape needed no change (Fig. 10)
8 [3, 3*, 2]	Low crease; deep (rare)*/or shallow scar; shape change to NJC
7 [3, 3, 1]	Low crease; shallow scar; shape change to parallel (or create a crease medially) (Fig. 11)
6 [3, 3, 0]	Low crease; shallow scar; has crease shape that needed no change (Fig. 12)
5 [5, 0, 0]	High crease; scar depth acceptable; shape acceptable (Fig. 13)
5 [3, 0, 2]	Low crease; scar depth acceptable; shape change to NJC
5 [0, 3, 2]	Crease height normal; revise deep/shallow scar; shape change to NJC
4 [3, 0, 1]	Low crease; depth of scar acceptable; shape change to parallel (or create a crease medially) (Fig. 14)
4 [0, 3, 1]	Height is normal; revise deep/shallow scar†; shape change to parallel (or create a crease medially).
3 [3, 0, 0]	Low crease height
3 [0, 3, 0]	Revise deep/shallow mid-lamellar scar (may follow reasonable previous Asian blepharoplasty.) (Fig. 15)
2 [0, 0, 2]	Shape change from parallel to NJC (difficult with skin shortage)
1 [0, 0, 1]	Shape change from NJC to parallel (or to complete the formation of medial portion of a crease) (Fig. 16)

Each bracketed set of 3 numbers refers to the level of difficulty (score) assigned to the 3 factors (height, depth of the scar or crease formed, and shape of crease) for each lid. The number preceding the bracket is the sum (H + D + S) of the component scores and is listed in descending order, with higher values being more challenging. 8 [3, 3*, 2], the combination of a low crease with deep scar in the pretarsal zone is rare and the solutions challenging; it may require clearance of scar adhesion in the pretarsal zone and addition of adipose strands, and for extreme cases, the use of full thickness skin grafts that are exquisitely thinned. More often, a low crease height is accompanied by a shallow scar or absence of superficial mark, though they may have deeper mid-lamellar scarring.

†May have arisen from regression following placement of buried sutures.

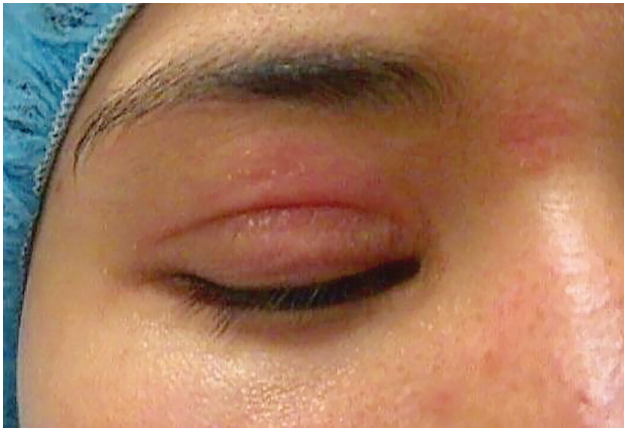

Fig. 8. RES of 10: 30-year-old woman {5, 3, 2}; high, deep, parallel with persistent pretarsal swelling; desired NJC shape.

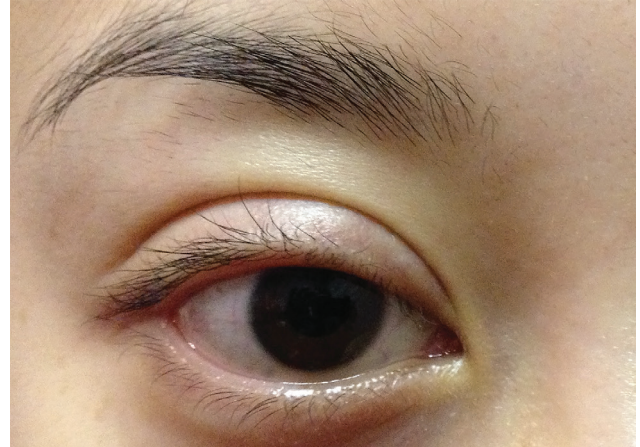

Fig. 10. RES of 8: 25-year-old woman {5, 3, 0}; high and deep; stayed with nasally joining shape.

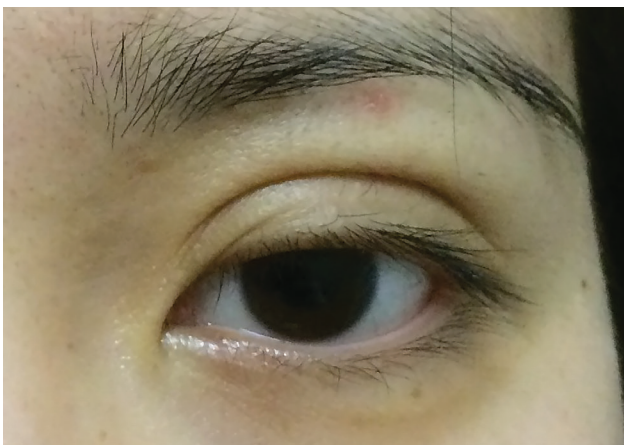


Fig. 9. RES of 9: 27-year-old woman {5, 3, 1}; high semicircular, deep; convert to parallel shape.

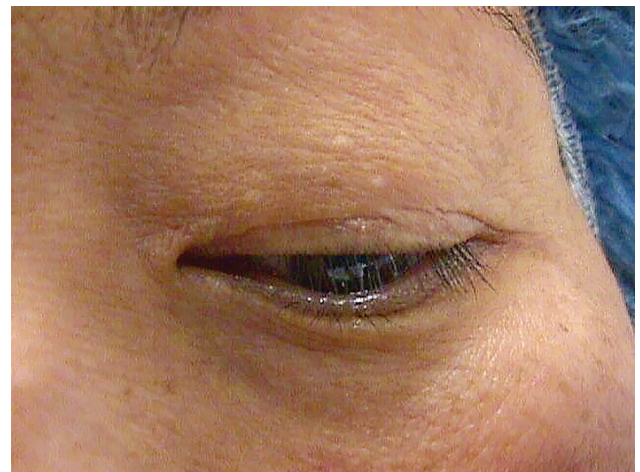

Fig. 11. RES of 7: 50-year-old woman {3, 3, 1}; had incisional method. Low, shallow, nasally joining crease shape. Preferred higher crease height and convert to parallel shape.

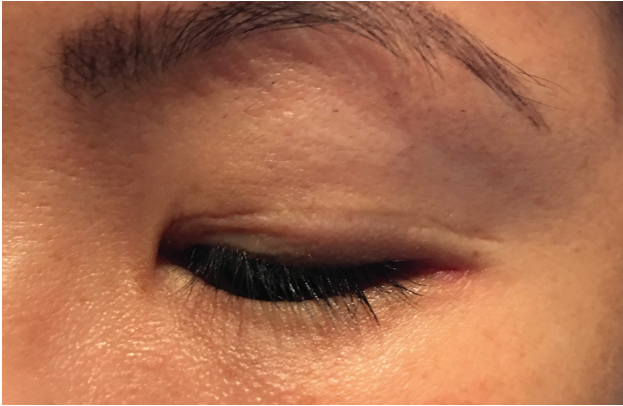

Fig. 12. RES of 6: 31-year-old woman {3, 3, 0}; low crease, deep-set wound scar, with significant induration and medial fold more than 1 year beyond prior procedure. Stayed with NJC.

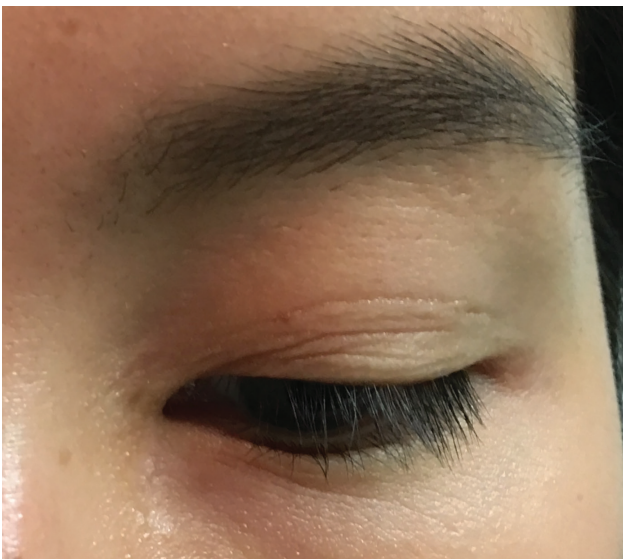


Fig. 13. RES of 5: 28-year-old woman {5, 0, 0}; 10 years after sutures method; high crease height with multiple lines; stayed parallel.

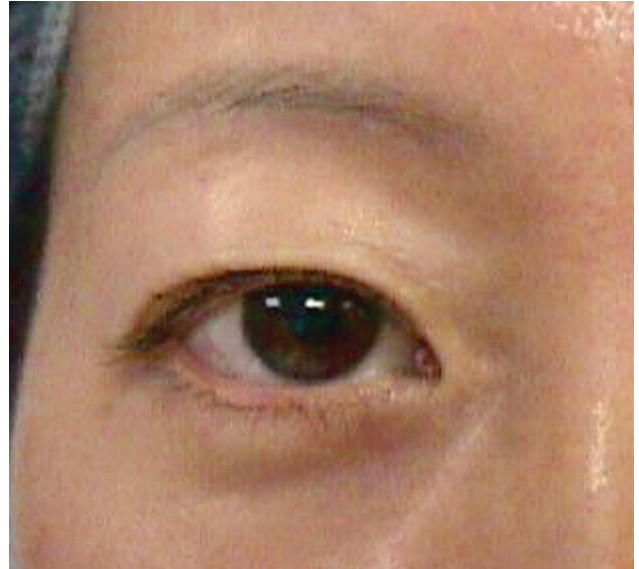

Fig. 14. RES of 4: 40-year-old woman {3, 0, 1}; had sutures method. Low crease height, nasally tapered; stay with NJC and needed medial fold reduction.

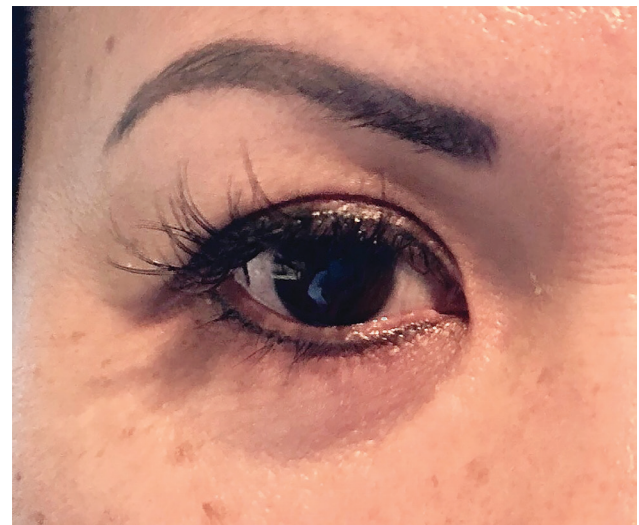

Fig. 15. RES of 3: 50-year-old woman {0, 3, 0} 15 years after incisional Asian blepharoplasty at 35 y.o. Repeated blepharoplasty with crease height of 7.5 mm, NJC shape.

3. The scoring can be expanded to those *easier revisions*: the effort to revise a high crease height with residual skin can be assigned an easier score (ceiling) of 4 or 3 in the height category, instead of 5 as in this series, where there were no residual skin left; maximal {H + D + S} scores will be reduced to 9 or 8.
4. This scoring system's rules can be easily learned and applied to any upper lid post-blepharoplasty issues that involved the lid crease portal.

The flexible range of this revisional scoring system can accommodate as well as differentiate factors among challenging cases, and this is the prime reason behind why the author has adopted this system.

LIMITATIONS

This is a limited series with strict inclusion criteria that took 13.5 years to accumulate. Easier revisions with

redundant skin were not included in this study. Such a scoring scale is qualitative by nature and requires subjective grading. Personal experience over 3 decades influenced how the author assigned the numerical scale of 5, 3, 2, and 1 to the variables of height, depth of scar, and shape.

CONCLUSIONS

Revisional Asian blepharoplasty for high crease *height* with little skin left behind is the most challenging scenario faced by surgeons. Other challenges include moving a low-set crease to a higher position, clearance of mid-lamellar *scarring*, and enhancement of crease *shape*. This

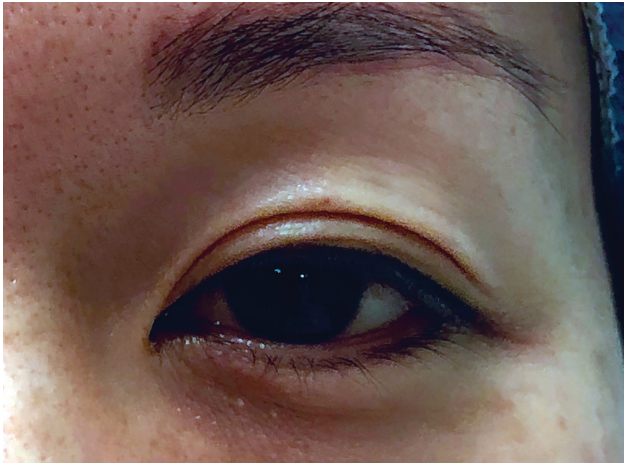


Fig. 16. RES of 1: 40-year-old woman {0, 0, 1}; 10 years after external incisional upper blepharoplasty at 30 years. Preferred change to parallel shape.

Super-beveled revisional A.B. (W.P.D. Chen)

- (i) Lysis of adhesions through 2 planes
- (ii) Release and reset

Reach
Reposit
Remove
Reset
Recruit
Restore

Fig. 17. Sequential steps after first traversing through 2 fascial planes (the skin-orbicularis oculi scar and orbicularis-orbital septum-fat scar) in the super-beveled approach in revisional Asian blepharoplasty, by Chen.^{30,31} "Restore" refers to improvement in the (preseptal/pre tarsal) ratio or (upper/lower segment) ratio.

is a novel work to explore the *front-end* assessments and to provide a system of categorization of these pre-revisional findings. This study presents an HDS scoring system that is simple to apply and is of value in assessment, patient counseling, and research. It is my hope that it can generate greater understanding of factors involved in upper blepharoplasty.

William Pai-Dei Chen, MD
 18 Endeavor, Suite 305
 Irvine, CA 92618
 E-mail: wpdchen@ucla.edu

REFERENCES

1. Mikamo K. *A Technique in the Double Eyelid Operation*. J Chugaishinpo. 1896;396:9.
2. Fernandez LR. Double eyelid operation in the Oriental in Hawaii. *Plast Reconstr Surg Transplant Bull*. 1960;25:257-264.
3. Boo-Chai K. Further experience with cosmetic surgery of the upper eyelid. Paper presented at: Proceedings of the Third International Congress of Plastic Surgery, Washington,

- D.C., October 13-19, 1963. Reprinted from *Excerpta Medica International Congress Series No. 66*; 1963:518.
4. Koornneef L. Details of the orbital connective tissue system in the adult. *Acta Morphol Neerl Scand*. 1977;15:1-34.
5. Collin JR, Beard C, Wood I. Experimental and clinical data on the insertion of the levator palpebrae superioris muscle. *Am J Ophthalmol*. 1978;85:792-801.
6. Siegel R. Surgical anatomy of the upper eyelid fascia. *Ann Plast Surg*. 1984;13:263-273.
7. Meyer DR, Linberg JV, Wobig JL, et al. Anatomy of the orbital septum and associated eyelid connective tissues. Implications for ptosis surgery. *Ophthalmic Plast Reconstr Surg*. 1991;7:104-113.
8. Hwang K, Kim DJ, Chung RS, et al. An anatomical study of the junction of the orbital septum and the levator aponeurosis in Orientals. *Br J Plast Surg*. 1998;51:594-598.
9. Jeong S, Lemke BN, Dortzbach RK, et al. The Asian upper eyelid: an anatomical study with comparison to the Caucasian eyelid. *Arch Ophthalmol*. 1999;117:907-912.
10. Cheng J, Xu FZ. Anatomic microstructure of the upper eyelid in the Oriental double eyelid. *Plast Reconstr Surg*. 2001;107:1665-1668.
11. Morikawa K, Yamamoto H, Uchinuma E, et al. Scanning electron microscopic study on double and single eyelids in Orientals. *Aesthetic Plast Surg*. 2001;25:20-24.
12. Chen WPD. Asian blepharoplasty—anatomy & technique. *Ophthalmic Plast Reconstr Surg*. 1987;3:135-140.
13. Zubiri JS. Correction of the Oriental eyelid. *Clin Plast Surg*. 1981;8:725-737.
14. Zubiri JS. Subdermal placement of sutures in double eyelid surgery. *Aesthet Surg J*. 2013;33:722-732.
15. Chen WPD. Concept of triangular, rectangular & trapezoidal debulking of eyelid tissues: application in Asian blepharoplasty. *Plast Reconstr Surg*. 1996;97:212-218.
16. Chen WPD. Primary double eyelid surgery—trapezoidal de-bulking of upper eyelid tissues. *Plast Reconstr Surg Glob Open*. 2018;6:e1780.
17. Chen WPD. A comparison of Caucasian & Asian blepharoplasty. *Ophthalmic Practice*. 1991;9:216-222.
18. Chen WPD. Aesthetic eyelid surgery in Asians: an East-West view. *Hong Kong J Ophthalmol*. 2000;3:27-31.
19. Flowers RS. Upper blepharoplasty by eyelid invagination. Anchor blepharoplasty. *Clin Plast Surg*. 1993;20:193-207.
20. Johnson CC. Epicanthus. *Am J Ophthalmol*. 1968;66:939-946.
21. Chen WPD. Recent literature on epicanthoplasty (listing 16 papers in English): appendix 4. In: *Asian Blepharoplasty and the Eyelid Crease*. 3rd ed. Edinburgh/New York: Elsevier; 2016:366-371.
22. Seo JD, Kim JH, Pak CS, et al. Medial epicanthoplasty using the "inside-out" technique. *J Plast Surg Hand Surg*. 2014;48:139-142.
23. Chung YJ, Han KE, Park BY. Restoration of complicated epicanthus: modified reverse skin redraping with mini-epicanthoplasty for rescue in unsatisfied epicanthoplasty patients. *Ann Plast Surg*. 2017;78:613-617.
24. Yoon CH, Na MH, Kim WS, et al. Epicanthoplasty with three-dimensional Z-plasty. *J Korean Soc Aesthetic Plast Surg*. 1997;3:67-73.
25. Boo-Chai K. *Secondary Blepharoplasty in Orientals: Problems in Plastic and Reconstructive Surgery*. Philadelphia, PA: Lippincott; 1991:520-535.
26. Boo-Chai K. Perioperative bleeding in the pre-tarsal (post-aponeurotic) space in Oriental blepharoplasty. *Br J Plast Surg*. 2001;54:370.
27. Kim BG, Yoon D, Yoon ES, et al. Unexpected bleeding caused by arterial variation inferolateral to levator palpebrae. *Aesthetic Plast Surg*. 2003;27:123-125.
28. Hwang K, Kim BG, Kim YJ, et al. Lateral septoaponeurotic artery: source of bleeding in blepharoplasty performed in Asians. *Ann Plast Surg*. 2003;50:156-159.

29. Kawai K, Imanishi N, Nakajima H, et al. Arterial anatomical features of the upper palpebra. *Plast Reconstr Surg.* 2004;113:479–484.
30. Chen WPD. Beveled approach for revisional surgery in Asian blepharoplasty. *Plast Reconstr Surg.* 2007;120:545–552.
31. Chen WPD. Super-beveled approach in revisional Asian blepharoplasty. In: *Asian Blepharoplasty and the Eyelid Crease.* 3rd ed. London: Elsevier; 2016:258.
32. Chen WPD. The concept of a glide zone as it relates to upper lid crease, lid fold, and application in upper blepharoplasty. *Plast Reconstr Surg.* 2007;119:379–386.
33. Chen WPD. Revisional Asian blepharoplasty—bevelled approach and resetting of eyelid lamellas. *Plast Reconstr Surg Glob Open.* 2018;6:e1785.
34. Kruavit A. Asian blepharoplasty: an 18-year experience in 6215 patients. *Aesthet Surg J.* 2009;29:272–283.
35. Chen WPD, Park JD. Asian upper lid blepharoplasty: an update on indications and technique. *Facial Plast Surg.* 2013;29:26–31.
36. Chang SH, Chen WPD, Cho IC, et al. Comprehensive review of Asian cosmetic upper eyelid oculoplastic surgery: Asian blepharoplasty and the like. *Arch Aesthetic Plast Surg.* 2014;20:129–139.
37. Rohrich RJ, Villanueva NL, Afroz PN. Refinements in upper blepharoplasty: the five-step technique. *Plast Reconstr Surg.* 2018;141:1144–1146.
38. Kim YW, Park HJ, Kim S. Secondary correction of unsatisfactory blepharoplasty: removing multilaminated septal structures and grafting of preaponeurotic fat. *Plast Reconstr Surg.* 2000;106:1399–1404; discussion 1405.
39. Chen S, Mardini S, Chen HC, et al. Strategies for a successful corrective Asian Blepharoplasty after previously failed revisions. *Plast Reconstr Surg.* 2004;114:1270–1277.
40. Kim BG, Youn DY. Management of adhesion using a pretarsal fibromuscular flap or graft in secondary blepharoplasty. *Plast Reconstr Surg.* 2006;117:782–789; discussion 790.
41. Zhang Y, Yuan L, Sun B, et al. Repair of unsatisfactory double eyelid after double-eyelid blepharoplasty in Asian patients. *Arch Facial Plast Surg.* 2010;12:236–240.
42. Cho IC. Revision upper blepharoplasty. *Semin Plast Surg.* 2015;29:201–208.
43. Young SM, Kim YD, Kim JH, et al. Lowering of the high eyelid crease in revision upper eyelid surgery. *Aesthetic Plast Surg.* 2019;43:139–146.
44. Chen WPD. Visual, physiological, and aesthetic factors and pitfalls in Asian blepharoplasty. *Aesthet Surg J.* 2016;36:275–283.
45. Chen WPD. Techniques, principles and benchmarks in Asian blepharoplasty. *Plast Reconstr Surg Glob Open.* 2019;7:e2271.
46. Chen WPD. Chapters 4, 15, & 20; Figures 4-2, 15-16, 20-11 on vulnerability of Asian eyelid anatomy. In Chen WP-D, ed.: *Asian Blepharoplasty and the Eyelid Crease.* 3rd ed. Edinburgh/New York, NY: Elsevier; 2016.
47. Chen WPD. Correction of eyelid crease height abnormalities, in Chapter 7: revision and correction of suboptimal results. In Chen WP-D, ed.: *Asian Blepharoplasty: A Surgical Atlas.* Butterworth-Heinemann, Reed Elsevier Group; 1995:81–101.